

Allgrove syndrome

Dr Aboulgasem EM Elgerbi

Pediatric Department - Faculty of Medicine

Zawia University

Abstract :

Allgrove's or Triple A syndrome (AS), is a rare autosomal recessive condition characterized by alacrima, achalasia, autonomous neuropathy and ACTH insensitivity among other features .

The syndrome usually presents during the first decade of life with severe (occasionally fatal) hypoglycaemic or hypotensive attacks, dysphagia, while other signs may be delayed until adulthood. In contrast with early childhood patients, adolescent patients with Allgrove's syndrome may present with multisystem neurological disease; the childhood history of achalasia or alacrima may be overlooked .

This report describes a 15-year-old girl who was admitted to Zawia teaching hospital for evaluation of recurrent pneumonia and hypoglycemia

, and was finally diagnosed as AS. Early recognition of this syndrome permits effective management of unrecognized autonomic dysfunction, adrenal insufficiency and dysphagia, and appropriate genetic advice.

INTRODUCTION :

Allgrove syndrome (AS), also known as 3A syndrome (AAAS) is rare an autosomal recessive disorder . It was first described by Allgrove et al in 1978 .¹ The *AAAS* gene is coded on chromosome 12q13 and mutation in the *AAAS* gene results in insufficiency in the protein function known as aladin or adracalin.²

The disease is characterized by adrenocorticotrophic hormone (ACTH)-resistant adrenal insufficiency, alacrima and achalasia.

The onset of adrenocortical impairment is usually before puberty, although preservation of cortisol secretion into the third decade has been reported.³ The syndrome may thus manifest itself during the first decade of life with severe hypoglycaemic or hypotensive attacks, which may lead to sudden death. In addition several authors published description of a more global autonomic disturbance associated with the original Allgrove triad suggesting the name (4A) syndrome (adrenal insufficiency, achalasia, alacrima and autonomic abnormalities).^{4,5}

AS may be an under diagnosed multi-system disorder in which achalasia and alacrima are the most valuable clinical signs to reach the diagnosis. Catastrophic complications can be prevented with adequate cortisol and specific measures such as pneumatic dilatation or myotomy along with other supportive management. The prognosis for health and quality of life can be significantly improved.

This report describes a 15-year-old girl with this disorder suffering from upper and lower motor neuron diseases, autonomic dysfunction,

muscle weakness, seizure, and ataxia primarily involving distal lower limbs.

Case Report

A 15-year-old girl is the twelfth child of healthy consanguineous parents and product of full-term delivery, was brought to the hospital emergency with the chief complaints of fever and cough for 3 days and breathlessness for 1 day. Fever was associated with chills and increased vomiting.

She was admitted to hospital several times for recurrent pneumonia and hypoglycemia.

At age of 4 she developed generalized hyper pigmentation . She was felt to have delayed developmental milestones and subsequently learning difficulties at school. Later on, the family noticed the progressive nasal speech and anorexia and lack of weight gain with frequent regurgitation. At the age of 10, she experienced a generalized tonic-clonic seizure.

Family history revealed sudden death of two sisters and one brother around 3 years of age without any definitive diagnosis.

On examination,. She was pale, unwell with severe respiratory distress and oxygen saturation was less than 90%, severely undernourished.

Her blood pressure was 80/50 mmHg. with postural drop to 50 mmHg , Chest examination showed intercostal and sub costal retraction, decreased air entry on left infrascapular area and crepitation bilaterally and heart examination revealed tachycardia.

Her height and weight were less than 5th centile and pubertal stage was II (breast and pubic hair). A neurological examination revealed mixed motor neuron abnormalities ,with symmetrical four limb weakness,

predominantly distal muscle wasting ,bilateral pes cavus , hyperreflexia, positive Babinski reflexes, right side facial palsy , dysarthria and ataxic gait. Direct questioning confirmed alacrima present from early infancy .

The basic laboratory findings were as follows: haemoglobin 9 mg/dL ; plasma glucose 30 mg/dL; blood urine nitrogen 51 mg/dL; creatine 1.4 mg/dL ; sodium 132 mmol/L potassium 4.3 mmol/L, C-reactive protein 120mg/L, insulin 5mu/l, cortisol 50 nmol/L and ACTH level was 864 pg/ml. Figure.1

Severe pneumonia was detected by chest X-ray. No bacterial growth in the blood culture was detected at admission. Supportive care, and cefatexime 2 g/day was administered . The patient was assessed to have adrenal crisis, and glucocorticoid treatment was administered.

Barium swallow confirmed achalasia (Figure. 2) and MRI showed adrenal gland hypoplasia. MRI of the brain and cervical spine was normal except for mild cerebellar atrophy and her EEG showed focal changes .

On the basis of above findings the diagnosis of Allgrove syndrome was made.She was given methyl cellulose eye drops and calcium channel blocker (nifedipine) 5mg twice daily and cortisol replacement therapy, prednisolone 10 mg /day to start with and subsequently dose was reduced to 5 mg/ day, with which her serum cortisol level was maintained within normal range. On follow up after 5 months she had gained 5 kg weight and there was decrease in skin pigmentation. She was re-ferred to pediatric surgeon for further management of achalasia

Figure.1 Patient's blood test results:

Investigation	Results	Reference values
Hb	9 mg /dl	12-15 mg/d
C-reactive protein	120mg/L	0-5 mg/L.
Blood sugar	30 g /dl	75- 110 mg /dl
Sodium	132 mmol/L	135-145 mmol/L
Potassium	4.3 mmol/L	3.5-5.0 mmol/L
Chloride	102 mmol/L	95-107 mmol/L
Bicarbonate	24 mmol/L	23-32 mmol/L
Urea	20mg/dl	8-20 mg/dL
Creatinine	1.4 mg /dl	0.4-1.0 mg/dL
Insulin	5 mU\ l	7-20 mu/l
Cortisol (08:00 h)	50 nmol/L	200-750 nmol/L
Adrenocorticotrophic hormone	864 pmol/L	< 20 pmol/L

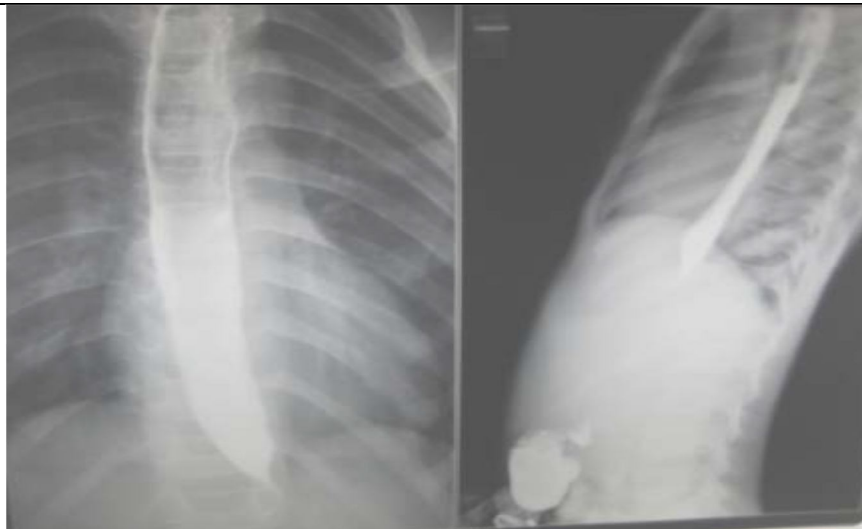


Figure 2: Showing stricture and dilation of lower end of the esophagus

Discussion :

Allgrove's syndrome is considered an autosomal recessive disorder with variable presentations. Link analysis in 12 triple-A families mostly originating from North Africa confirmed that the disease maps to the 12q13 region and suggested that triple-A is a genetically homogeneous disorder.⁶ The age of onset of symptoms is variable, the syndrome usually presenting during the first decade of life with dysphagia or severe (occasionally fatal) hypoglycemic or hypotensive attacks related to adrenocortical insufficiency.^{7,8}

In this case, alacrima and hypoglycemia were the initial alarming symptoms and alcalasia causing vomiting, dysphagia, recurrent chest infection and failure to thrive, which required frequent hospital admissions. There are several reports in the literature of severe neurologic dysfunction like Peripheral motor and sensory neuropathy reveal muscle wasting, hyperreflexia, dysarthria, nasal speech, ataxia and autonomic dysfunction.⁹⁻¹² All these signs were noticed at the age of four in our case contributing significantly to her morbidity.

Etiology of the neuropathy in Allgrove's syndrome is obscure. At present, no explanation for the association of achalasia, alacrima and adrenal unresponsiveness to ACTH in the triple A syndrome is available. It has been thought that the ACTH receptor gene would provide the link to explain the association of the three main features of the syndrome, since there is evidence that ACTH has some neuropathic effects.¹³⁻¹⁷

Careful replacement of glucocorticoids in patients with adrenal insufficiency and management of achalasia either via endoscopic or surgical approach are cornerstones of the treatment.

During 3 year follow-up, our patient showed impressive improvement. She is able to perform her daily routines without any support, communicates well and has gained 25 kg.

Conclusion:

Allgrove's syndrome may be an underdiagnosed disorder. A high index of suspicion is required when patients present with such complex symptoms as failure to thrive (dysphagia), crying without tears (alacrima), nasal speech, dysarthria and ataxia (cerebellar dysfunction) and seizures (hypoglycemia). Early diagnosis and effective management can reduce the morbidity and motility of this condition.

References :

1. Allgrove J, Clayden GS, Grant DB, Macaulay JC. *Familial glucocorticoid deficiency with achalasia of the cardia and deficient tear production.* *Lancet* 1978; 1:1284-6
2. Khelif K, De Laet MH, Chaouachi B, Segers V, Vanderwinden JM. *Achalasia of the cardia in Allgrove's (triple A) syndrome: histopathologic study of 10 cases.* *Am J Surg Pathol* 2003; 27:667-72.
- 3 Moore P, Couch R, Perry Y, et al. *Allgrove syndrome: an autosomal recessive syndrome of ACTH insensitivity, achalasia and alacrima.* *Clin Endoc (Oxf)* 1991;34:107-14.
- 4 Gazarian M, Cowell CT, Bonney M: *The " 4A" syndrome: adrenocortical insufficiency associated with achalasia, alacrima, autonomic and other neurological abnormalities.* *Euro J Pediatric* 1995; 154: 18-23.
- 5 Grant D, Barnes N, Dumic M, et al. *Neurological and adrenal dysfunction in the adrenal insufficiency/alacrima/achalasia syndrome.* *Arch Dis Child* 1993;68:779-82.
- 6 Huebner A, Yoon SJ, Ozkinay F, et al. *Triple-A syndrome—clinical aspects and molecular genetics.* *Endocr Res.* 2000; **26**: 751 – 759.

7. Makari G, Hoffman WH, Carroll JE. Autonomic dysfunction and adrenocortical unresponsiveness to ACTH. *J Child Neurol.* 1988;3:174–6. [[PubMed](#)]
8. Lanes R, Plotnick LP, Bynum TE. Glucocorticoid and partial mineral corticoid deficiency associated with achalasia. *J Clin Endocrinol Metab.* 1980;50:268–70.
- 9 Stratakis C, Lin J, Pras E, et al. Segregation of Allgrove syndrome in Puerto Rican kindreds with chromosome 12q13 polymorphic markers. *Proc Assoc Am Phys* 1997;109:478–82.
- 10 Longstreth G, Walker F. Mega-oesophagus and hereditary nervous system degeneration. *Clin Gastroenterol* 1994;19:125–7.
- 11 . Gazarian M, Cowell CT, Bonney M, Rigor WG. The “4A” syndrome: adrenocortical insufficiency associated with achalasia, alacrima, autonomic and other neurological abnormalities. *Eur J Pediatr.* 1995;154:18–23.
12. Chu ME, Berlin D, Axelrod FB. Allgrove syndrome: documenting cholinergic dysfunction by autonomic function tests. *J Pediatr.* 1996;129:256–9.
13. Bentes C, Santos-Bento M, de Sa J, et al. Allgrove syndrome in adulthood. *Muscle Nerve.* 2001;24:292–6.
14. Longstreth G, Walker F. Mega esophagus and hereditary nervous system degeneration. *Clin Gastroenterol.* 1994;19:125–7.
15. Deumic M, Radica A, Jusic A, et al. Selective ACTH insensitivity associated with autonomic nervous system abnormalities and sensorimotor polyneuropathy. *Eur J Pediatr.* 1987;146:592–4.
16. Stuckey B, Mastalgia F, Reed W, et al. Glucocorticoid deficiency, achalasia, alacrima with autonomic and motor neuropathy. *Ann Intern Med.* 1987;106:62–4.
17. De Weid D. Neurotropic effects of ACTH/MSH neuropeptide diseases. *Acta Neurobiol Exp.* 1990;50:353–66.