

Maternal Immunization During Pregnancy to Protect the Mother and Neonate in Rats

Dr. Mustafa A. Elsagri

*Community & family
medicine department
Faculty of Medicine*

Dr. Ahmed Khaled

*Anatomy department,
Faculty of medicine*

Zawia University

Abstract:

The Endometrium had been considered as feto-maternal interface special tissue during pregnancy. The aim of the present study is to investing at materno-fetal translocation of immunoglobulin G (Ig G) across the endometrium by ultra- structural immunocytochemistry. Fifty pregnant female rats were used in the present study. The endometrium on the end of 1st ,2nd & 3rd weeks of gestation (Term = 23 days), was examined by ultra-structural immunolabelling by using of gold conjugate.

In all stages of gestation, gold particles labeled Ig G were detected in the uterine lumen, in the luminal epithelium and in the sub-epithelium

stroma including stromal blood capillaries. The distribution and the amount of the gold particles labeling Ig G vary with different weeks of gestation. on the end of 1st week, the gold particles labeling Ig G were more seen in the apical cytoplasm and the uterine surface of the plasma membrane. on the end of 2nd week of gestation, gold particles labeling Ig G were seen in a significant amount in the luminal epithelium within vesicles and multivesicular bodies. on the end of 3rd week of gestation, abundant and large significant amounts of gold particles labeling Ig G were seen in the uterine lumen and in the apical cytoplasm, as well as in the sub-epithelial stroma and stromal blood capillaries.

Conclusion:

The concept of maternal immunization is a potential strategy to prevent infection in infants. The maternal immunization protects the neonate against illness in the first 3 – 6 months which is simple, straight forward and safe. Further evaluation of this strategy was supported by medical literature, but liability and educational barriers exist.

Introduction:

Maternal immunization could help to prevent 2 – 3 million neonatal and early infant deaths that occur in the developing world each year **(1)**. Determining the causes of neonatal and early infant deaths in developing countries is difficult as most occur at home. However, it is likely at least half are due to infection. Several of which might be prevented by maternal immunization **(2)**. Even in poor countries with few health facilities, a high percentage of pregnant women attend an antenatal clinic at least once during pregnancy. Thus, an effective delivery system for maternal immunization already exists and, because of the success of maternal tetanus

immunization, this approach to the prevention of serious illness or death in young infants is widely accepted by the general population (3). Thus, a strong case can be made for a trial of the effectiveness of maternal immunization in preventing serious illness or death in young infants in developing countries (4).

Maternal immunization provides protection to the newborn through the transfer of vaccine-induced Ig G across the placenta, a process that is affected by multiple variables. Maternal vaccination against tetanus, influenza and pertussis is recommended in U.K. and U.S. with new studies indicating their efficacy. A number of additional maternal vaccines are also in the pipeline, which could be used to combat neonatal infection. Recent research findings have highlighted some of the reasons for the poor uptake of current recommendations among pregnant women (5). Accordingly, the aim of the present study was to study the controlling cellular mechanisms for the uptake and materno-fetal translocation of immunoglobulin G (Ig G) across the endometrium by utilizing immunocytochemical methods.

Material & Methods:

Thirty adult female and ten adult male rats were used in the present study. Daily vaginal leavages were taken to identify the pre-estrus period in all adult female rats. Once an animal showed a lavage characteristic of the pre-estrus period, it was caged overnight with breeder males a second lavage was made in the next morning for identification of sperms. The day when sperms were identified was designated as the first day of gestation. The pregnant female rats were divided into three groups, each group includes ten rats. They were individually placed in a plastic cage in a room with a 12 hour light / dark cycle. Food and water were provided ad libidum.

The animals were subsequently sacrificed on the end of 1st, 2nd & 3rd weeks of gestation (Term = 23 days). In the day of autopsy, the rat was anaesthetized by a single intraperitoneal injection of sodium pentobarbital (0. 1 ml of aqueous solution per 100 gm body weight). The uterine horns were per fused with 4% par formaldehyde and 0.1 gluteraldehyde in 0.1 M phosphate buffer for fixation. After fixation, the endometrium was washed in sucrose buffer and dehydrated in ascending grade of ethanol. The capsules were undergone to infiltration at low temperature and then they were transferred to wire capsule holder for ultraviolet polymerization of monomeric lowicryl. Ultra thin sections were cut and were mounted on meshes copper grids. Immunolabelling was done according to (6).

Results:

I. First Week Of Gestation:

There was definite labeling of Ig G in the endometrium indicated by the presence of gold particles in both the luminal epithelial cells and in the endometrial stroma. Few gold particles were also seen to be localized in the uterine lumen. In the luminal epithelium, the gold particles were demonstrated in the apical part of the cells. Few particles were observed bound to the membranes of the invaginated pits at the bases of the microvilli and the apical vacuoles. However, a significant amount of gold was identified close to the apical part of the lateral plasma membranes (**Fig. 1**). Moreover, few gold particles were identified in the infra-nuclear cytoplasm along the basal plasma membrane in the luminal epithelial cells (**Fig. 2**). The endometrial stroma showed significant amounts of gold particles. They were demonstrated in the connective tissue close to the basement membrane and near to the blood capillaries. In addition, high

number of gold particles were seen freely within the lumen of the stromal blood capillaries (Figs. 2 & 3).

II. Second Week Of Gestation:

The gold particles were seen to be localized in both the luminal epithelium and the endometrial stroma. The luminal epithelium showed high concentration of gold particles. On the apical surface of the cells, the gold particles were seen to be closely associated with the membrane at the free surface of the cells. The microvilli also showed few gold particles on their surface (Fig. 4). No gold particles were identified at the base of the microvilli in the apical invaginated pits (Fig. 5). In addition, gold particles were seen in the apical coated vesicles as well as in the uncoated vacuoles and in the multivesicular bodies (Figs. 5 & 6). However, few particles were demonstrated at the basolateral plasma membrane. The gold particles were also identified in significant amounts in the endometrial stroma but they were highly localized in the stromal blood capillaries. Also, the gold particles were seen in both the endothelial cells and in the uterine lumen (Fig. 7).

III. Third Week Of Gestation:

The amount of immunoglobulin G labeled with gold particles was demonstrated and identified in high concentration than that in 1st and 2nd weeks of the gestation. Large number of gold particles were seen in the lumen of the uterus. They were also seen to be localized on the microvilli of the luminal epithelial cells and within the apical invaginated pits at the bases of the microvilli. Large number of gold particles were observed in the apical cytoplasm as well as along lateral plasma membrane (Fig. 8). However, no gold particles were demonstrated along the basolateral plasma membrane or in the coated vesicles near the basement membrane (Fig. 9).

Significant amounts of gold particles were identified in the sub – epithelial stroma. In the stromal blood capillaries, the gold particles were demonstrated in the endothelial cells as well as inside the uterine lumen (Fig. 10).

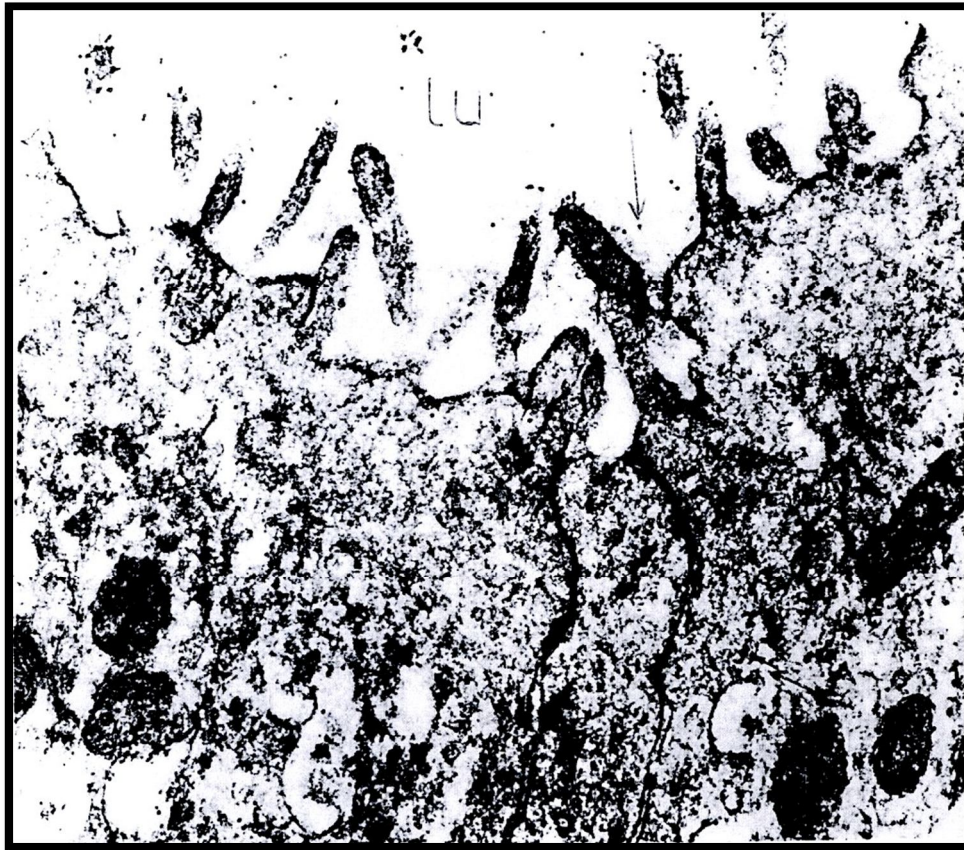


Figure (1):Immuno-electromicrograph of the rat uterine luminal epithelium on the end of 1st week of gestation labeled with gold for demonstration of Ig G showing localization of Ig G in the uterine lumen (**lu**)and in the apical cytoplasm (**short thick arrows**). Also, the gold particles are noticed in the invagination and near the apical plasma membrane (**long thin arrows**).

(X 30000)

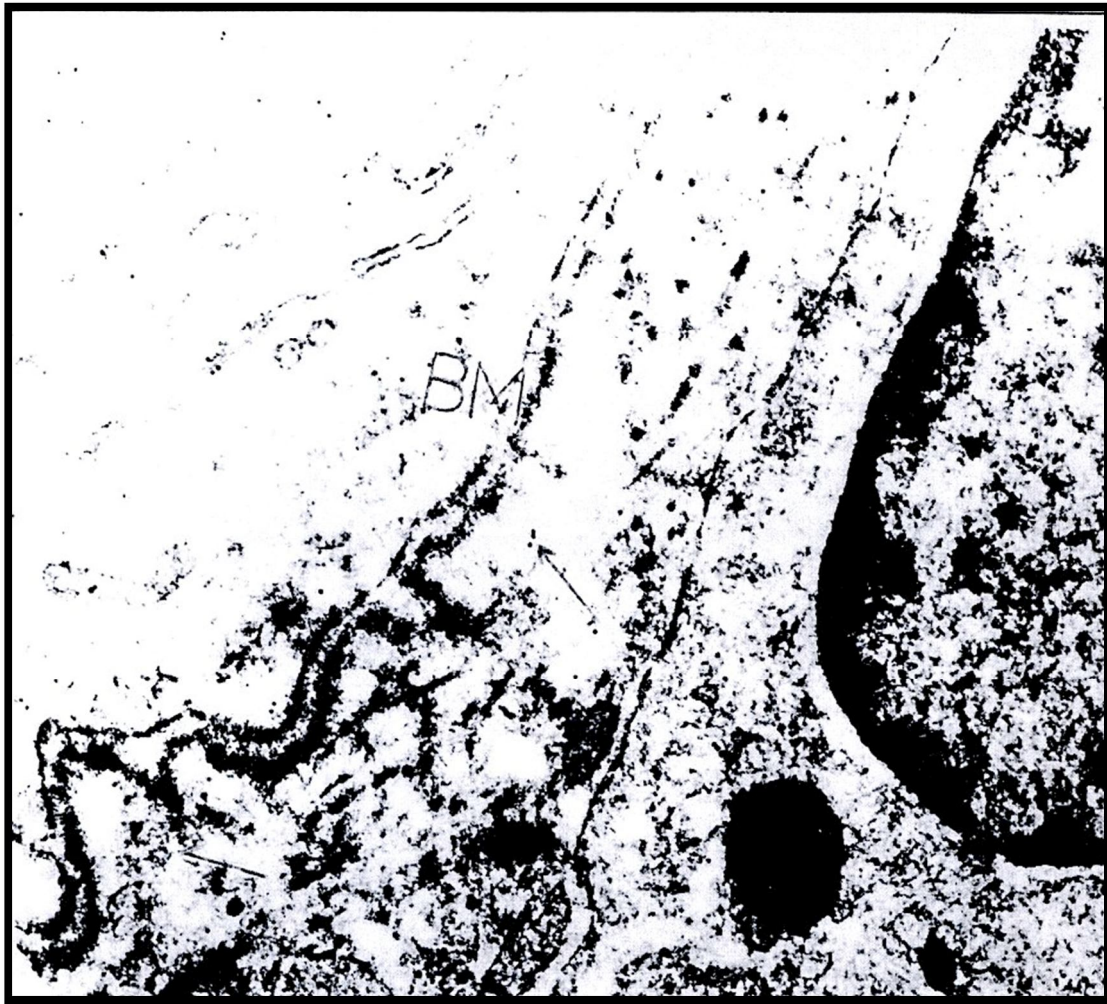


Figure (2):Immuno-electromicrograph of the rat on the end of the 1st week of gestation labeled with gold for demonstration of Ig G showing localization of gold particles along the basement membrane (**BM**). Notice the presence of gold particles in the subepithelial stroma(**arrows**).

X 30000

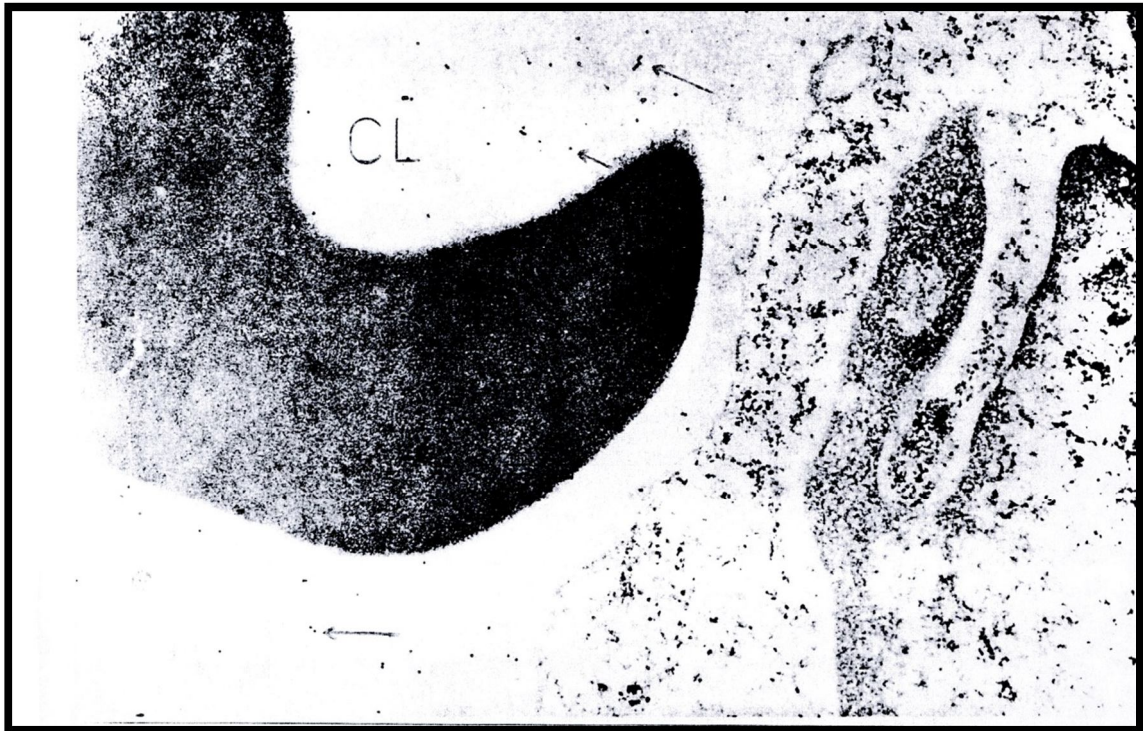


Figure (3): Immuno-electromicrograph of the rat endometrium on the end of the 1st week of gestation labeled with gold for demonstration of Ig G showing significant amount of gold particles (**arrows**) within the lumen of a stromal blood capillaries (CL).

X 30000

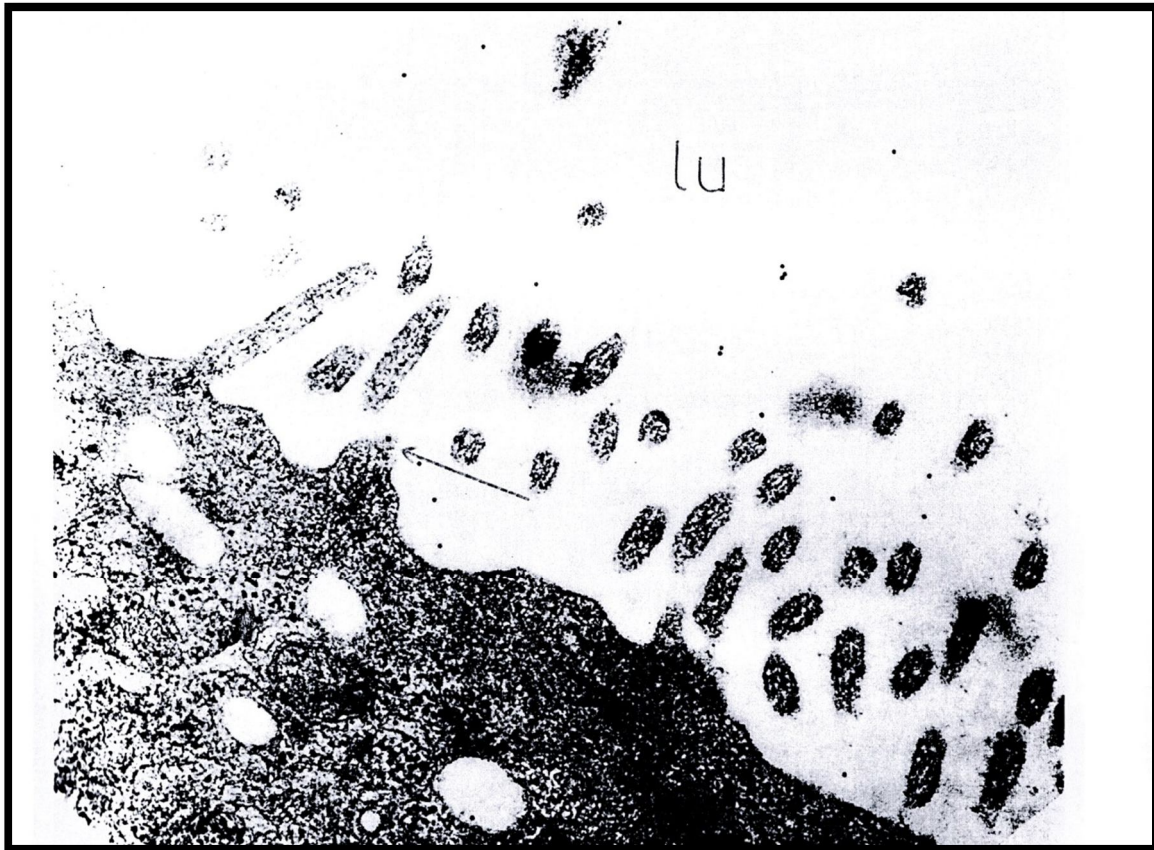


Figure (4): Immuno-electromicrograph of the rat uterine luminal epithelium on the 2nd week of gestation labeled with gold for demonstration of Ig G showing gold particles inside the uterine lumen (**lu**) , on the surface of the microvilli(**long narrow arrows**) and in the apical cytoplasm (**short thick arrows**).

X 30000

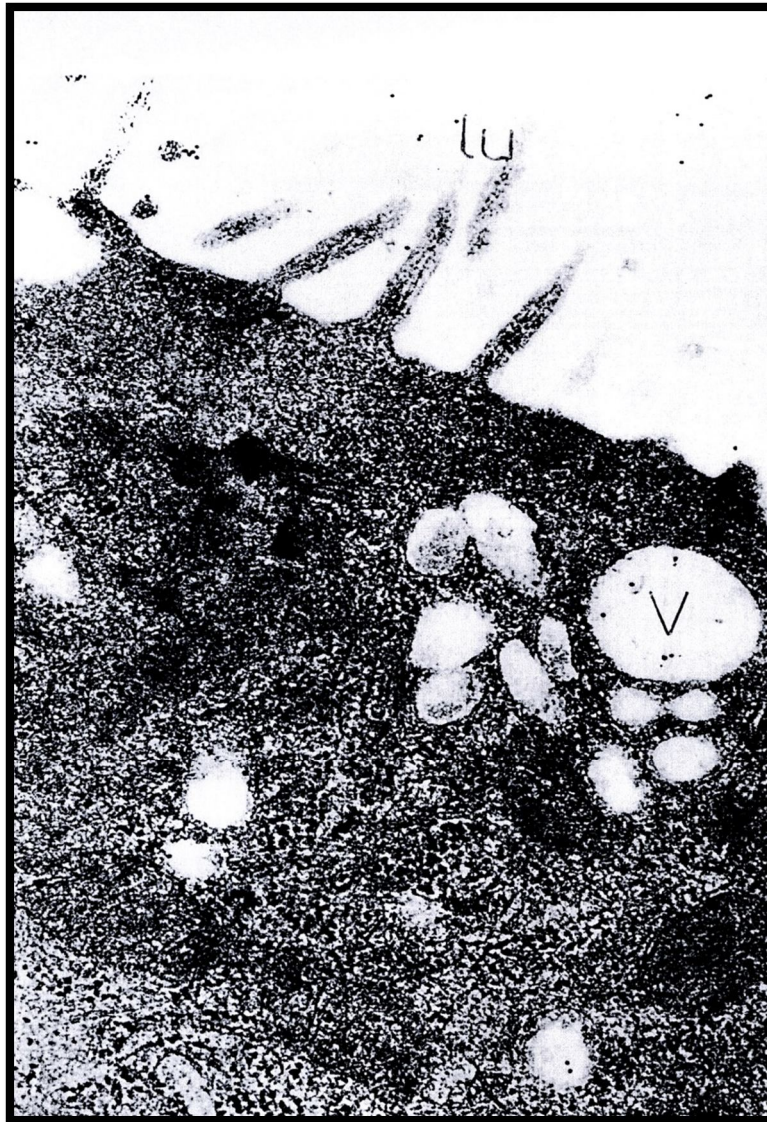


Figure (5):Immuno-electromicrograph of the rat uterine luminal epithelium on the 2nd week of gestation labeled with gold for demonstration of Ig G showing gold particles in the lumen (**lu**) and in the apical vacuoles (**V**).

X 30000

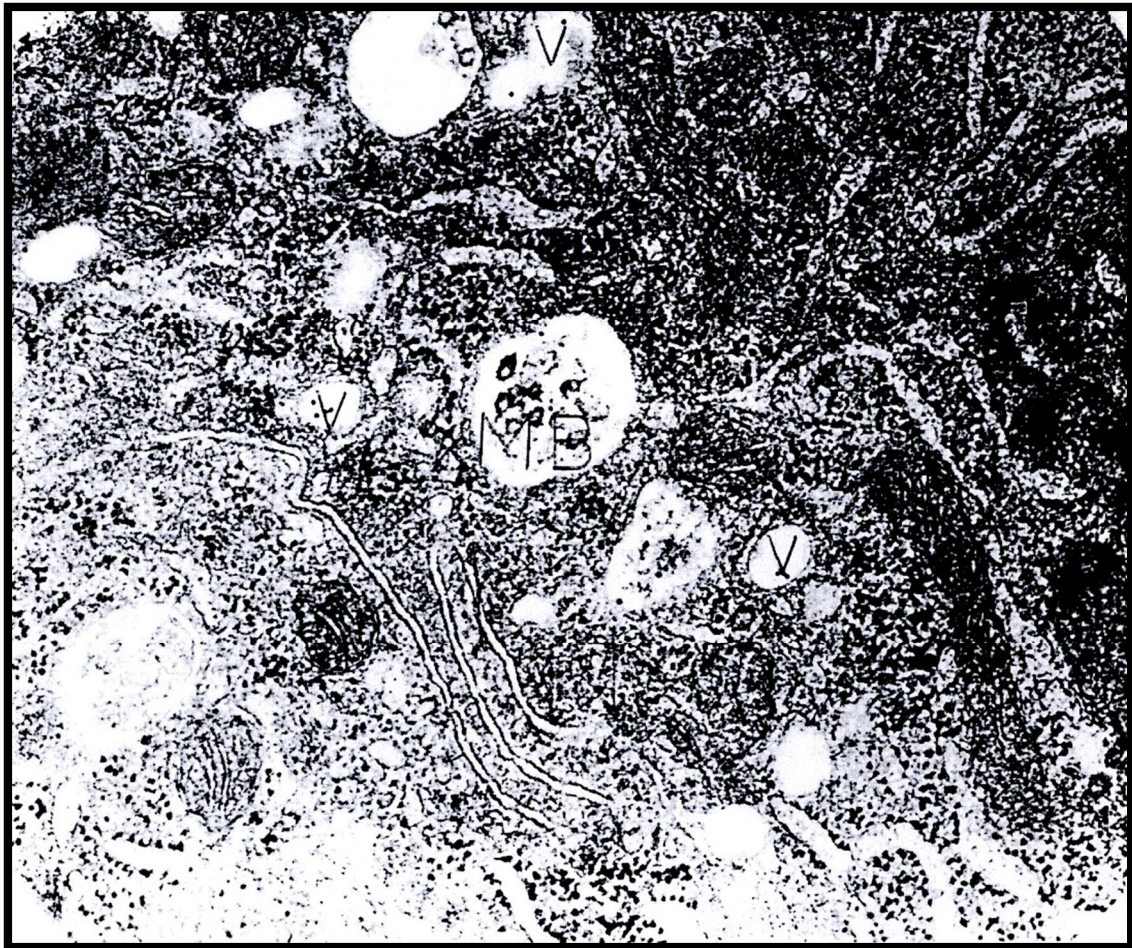


Figure (6): Immuno-electromicrograph of the rat uterine luminal epithelium on the end of the 2nd week of gestation labeled with gold for demonstration of Ig G showing gold particles within both the multivesicular body (**MB**) and the coated vesicles (**V**). Notice the presence of gold particles at the basolateral plasma membrane (**arrows**).

X 30000

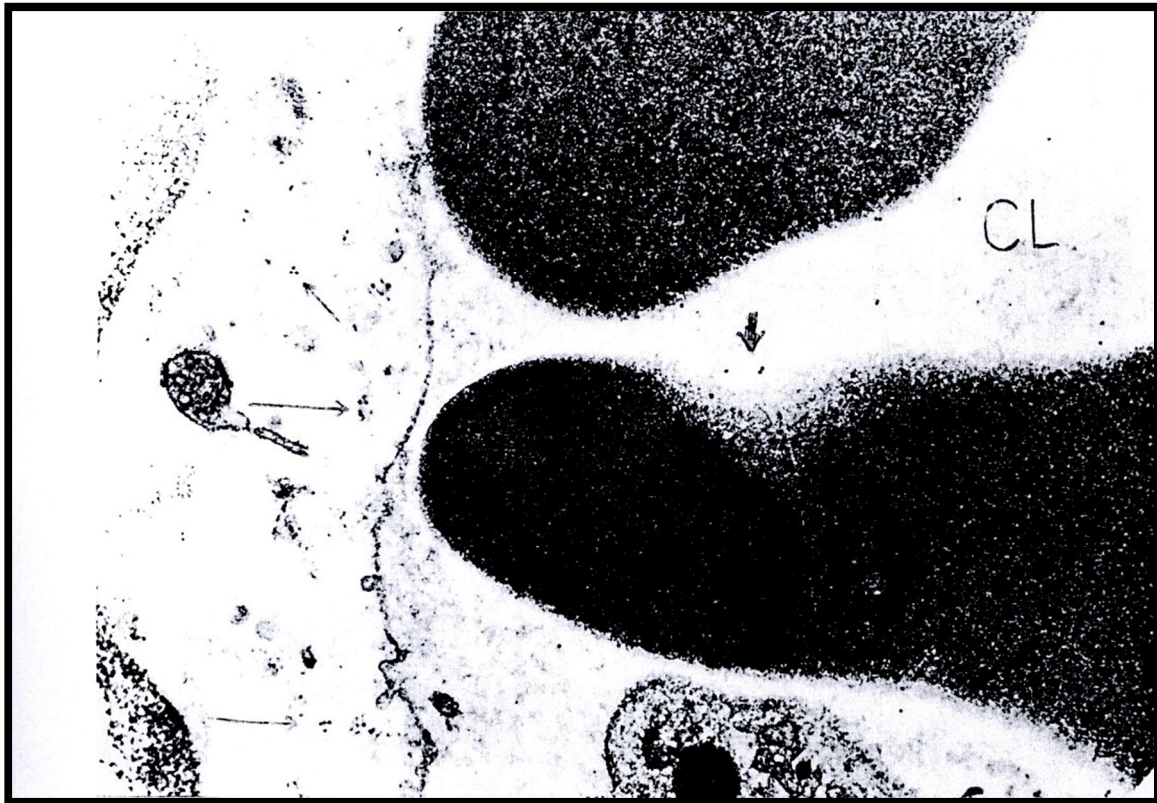


Figure (7): Immuno-electromicrograph of the rat uterine stromal capillary on the end of 2nd week of gestation labeled with gold for demonstration of Ig G showing a significant amount of gold particles (**short thick arrows**), inside the lumen of a stromal blood capillary (**CL**) and in the endothelial cell (**long thin arrows**).

X 30000

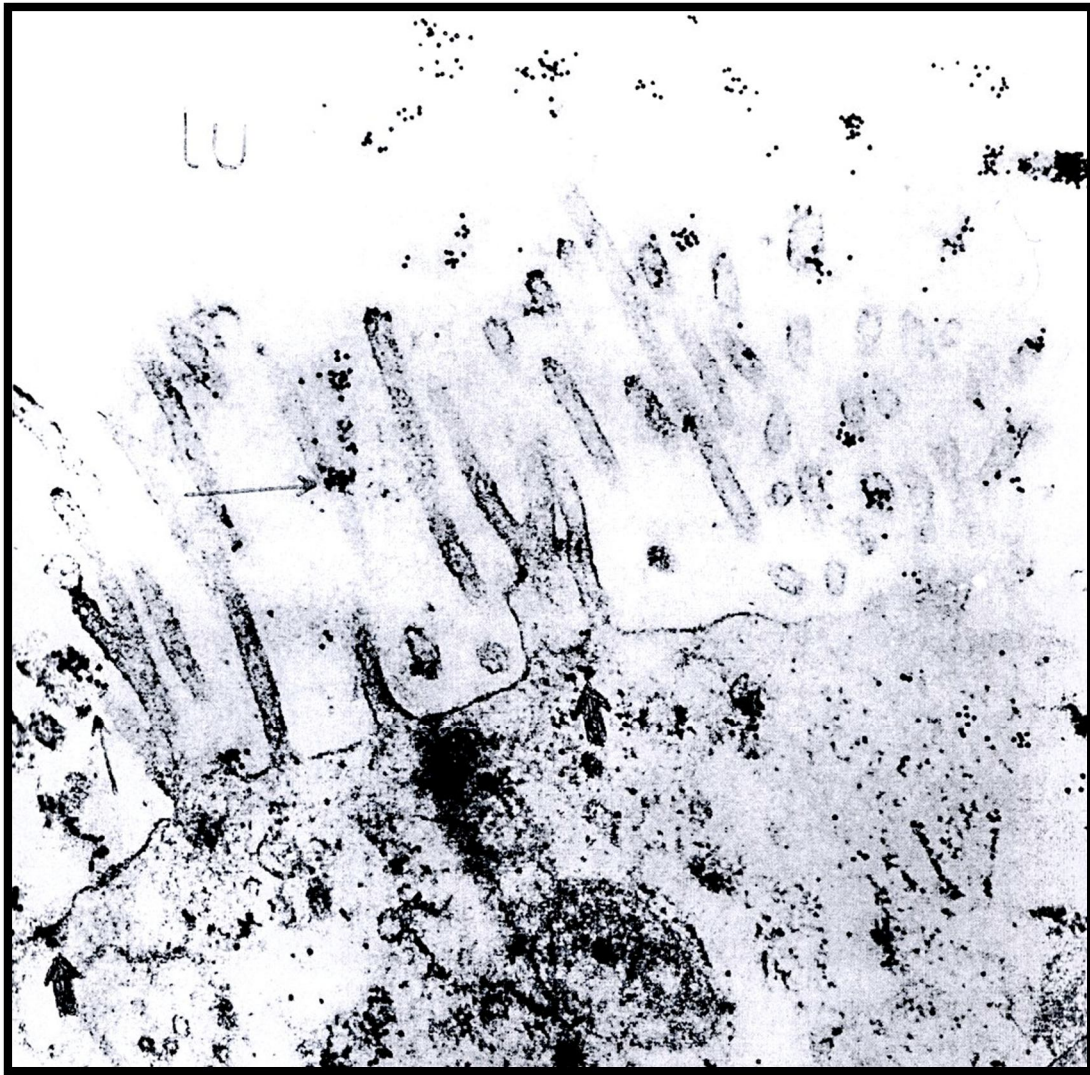


Figure (8): Immuno-electromicrograph of the rat uterine luminal epithelium on the end of 3rd week of gestation labeled with gold for demonstration of Ig G showing large number of gold particles inside uterine lumen (**lu**), on the surfaces of the microvilli (**long thin arrows**), at the bases of microvilli and at the apical invagination pits (**short thick arrows**).

X 30000

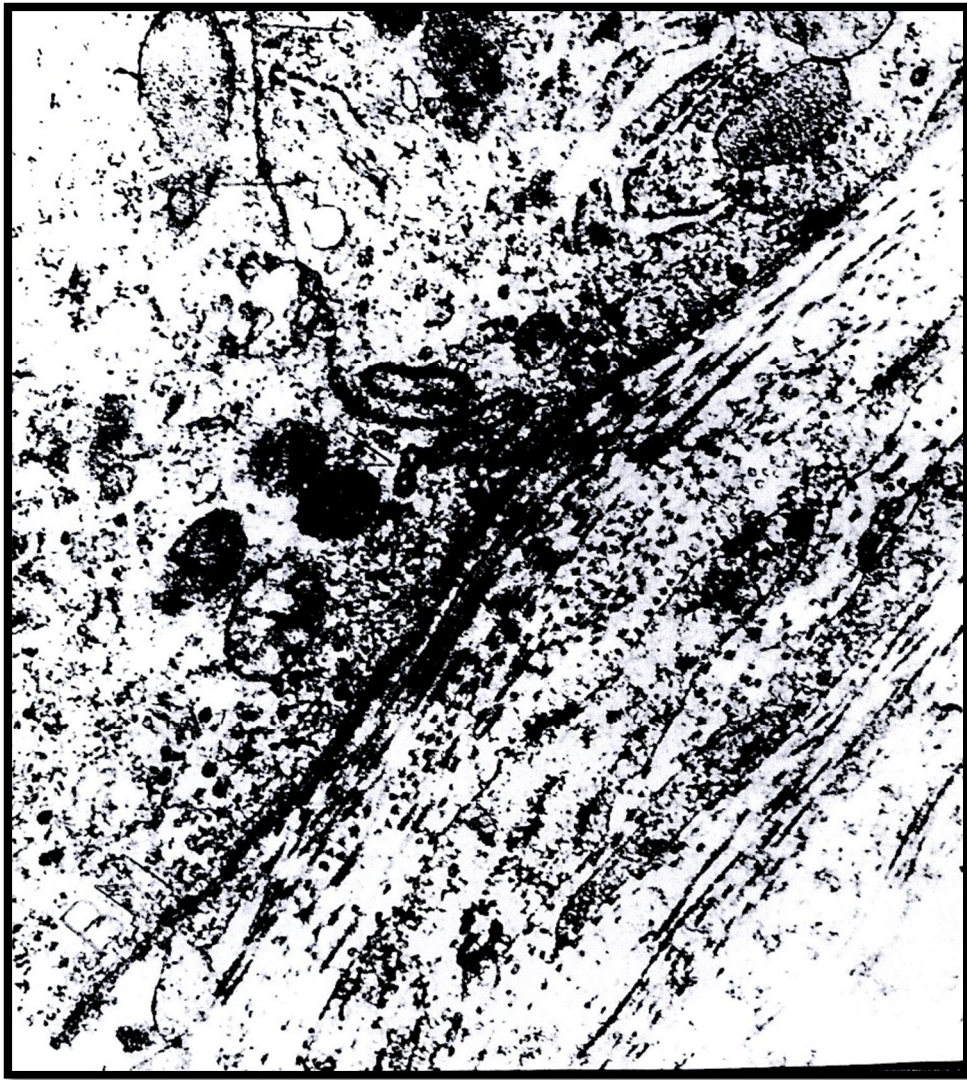

Figure (9):Immuno-electromicrograph of the rat uterine luminal epithelium on the end of 3rd week of gestation labeled with gold for demonstration of Ig G showing presence of gold particles in the sub-epithelial stroma(**arrows**). Notice that no gold particles are seen at the basal basement membrane (**BM**) or in the coated vesicles (**V**).

X 30000

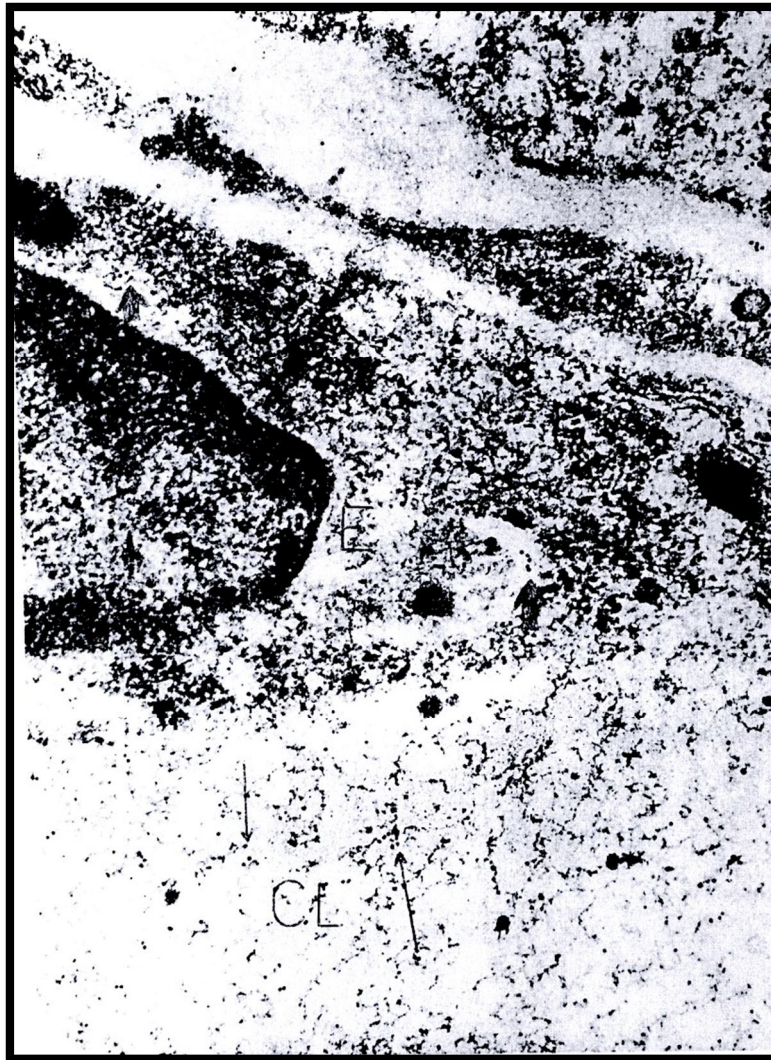


Figure (10): Immuno-electromicrograph of the rat uterine luminal epithelium on the end of 3rd week of gestation labeled with gold for demonstration of Ig G showing the lumen of a sub-epithelial blood capillary (CL) containing significant amount of gold particles inside its lumen (**long thin arrows**). Also, the endothelial cell (E) contains significant amount of gold particles (**short thick arrows**).

X 30000

Discussion:

At birth, most of the serum immunoglobulin G (Ig G) is derived from the transfer of maternal Ig G across the placenta during the pregnancy especially in 3rd trimester of pregnancy. As a result, serum Ig G level at birth is commonly equal to or slightly higher than maternal serum Ig G level(7). Small for gestational age neonates have somewhat lower Ig G level than full-term neonates, reflecting possible impaired placental transport (8 & 9). The concept of maternal immunization, to protect the mother against vaccine-preventable diseases and the neonate against illness for first 3 – 6 months, is simple, straightforward and safe (10). Therefore, appropriate maternal immunization and passive transferred antibodies to the fetus can protect until vaccination is more efficacious(11).

The rat was used as a model for passive immunization in mother for 3 reasons. First, considerable data are already available regarding the effects of passive immunization in the rat. Second, Ig G is readily transferred from mother to the fetus in both human and rats (12). Third, The placentas of the pregnant rat and human share several important features including a discoid anatomy and the absence of maternal tissue interposed between maternal blood and fetal tissues (13). In addition, both rat and human placentas have a transport system for the transfer of maternal Ig G to the fetus, which is absent in many other species (14, 15 & 16).

In mammals, the transfer of Ig G during gestation occurs through the placenta via the placental **Fc receptor** which lie on the placental syncytiotrophoblast. Also such receptors exist on the small intestine surface of some animals (as rats and mice) and functions to transfer ingested antibodies from maternal milk through enterocytes into serosal fluid and

ultimately into the systemic circulation (17). Neonatal Fc receptor was first identified in the 1970s as the protein that mediates transfer of maternal, milk-borne IgGs across the rodent neonatal intestine (18). Later, others have shown that Fc receptors play a central role in regulating the transport of Ig G within and across cells of diverse origin and it also serves to rescue Ig G from degradation, thereby prolonging its half-life (19). The mechanism was originally thought to be mediated mainly by endothelial cells, which line blood vessels. However, recent findings suggest that this process occurs also in hematopoietic cells or even in mammary epithelial cells during lactation (20).

In the present study, gold particles labeled Ig G were detected in the uterine lumen in all stages studies, reaching maximum on the end of 3rd week of gestation. In agreement with the results of the present work, (21) demonstrated Ig G and Ig A in the uterine lumen in the first half of pregnancy in the pregnant mice. (22) demonstrated Ig G bound to bacteria in the mouse uterine lumen on the morning after mating. The authors suggested that bacteria were probably introduced into the uterine lumen during mating and that local immune system may play a role in returning the uterus to an aseptic state before implantation. (23) reported that Ig G was identified in the uterine excretion of the pregnant humans. The author concluded that the transfer of Ig G occurs across the syncytiotrophoblast of the chorionic villi through the placental Fc receptors.

In the present study, gold particles detected in the luminal epithelial cells were seen to be localized at the surface membrane, at apical invagination pits and in the cytoplasm. At the end of 2nd week of gestation, gold particles were also detected in multivesicular bodies and in apical vacuoles. They were more abundant at the end of 3rd week of gestation. In

agreement with the present work, Ig G had been detected in the apical cytoplasm of uterine luminal epithelial cells in mouse (24), rats (25), sow (26) and rabbits (27).

In the present work, there was definite labeling of Ig G in the sub-epithelial stroma, in the endothelial cells of the blood capillaries. Gold particles were more abundant on the end of 3rd week of gestation. In agreement with the results of the present work, (28) reported that stromal Ig G probably was originated directly in the blood vessels and was accumulated in the tissue because of increased permeability of the blood capillaries at the time of implantation. (29 & 30) concluded that the neonatal Fc receptor is the only transporter of Ig G from the mother to the offspring in the mouse during gestation. (31 & 32) reported that neonatal Fc receptor regulates Ig G and albumin homeostasis, mediates maternal Ig G transport, takes active part in phagocytosis and delivers antigens for presentation in mice and rats. (33) reported that the major transfer of Ig G does not occur before 22nd week of pregnancy where the Fc receptor was weakly detectable during 1st trimester and increases progressively during pregnancy to reach its maximum during 3rd trimester. Also, (34 & 35) reported that vaccination of female rats before gestation or passive immunization during gestation can reduce the exposure of fetal brain to a single dose of maternally administered nicotine.

The future of Ig G transport during pregnancy is amazing, (36 & 37) reported that the neonatal immunization is largely unsuccessful due to immaturity of the infant's immune system. Therefore, appropriate maternal immunization and passive transferred antibodies to the fetus can protect the neonate until vaccination is more efficacious. (38,39 & 40) reported that the maternal immunization, is a potential strategy to prevent infection in

infants who have not completed their immunization from both specific infection of infancy and vaccine-preventable illnesses. (41, 42 & 43) could explain the efficacy of hyper-immune Ig G for treatment of tetanus, diphtheria, pertusis and cytomegalovirus infection during pregnancy and support vaccination. The results of these authors suggested that the antibodies of these diseases could disseminate to the placenta by co-opting Fc receptor mediated transport pathway of Ig G.

References:

1. Greenwood, B (2003): *Maternal immunization in developing countries. Vaccine, 21(24): 3436 – 41.*
2. Vandelaers, J; Birmingham, M, Gass, A et al. (2003): *Tetanus in developing countries: update on the maternal and neonatal tetanus elimination. Vaccine, 21(24): 2442 – 5.*
3. Roper, M; Vandelaar, J&Gasse, F (2007): *Maternal and neonatal tetanus. Lancet,370: 1947 – 59.*
4. Sule,S and Onayada,A (2006): *Community-based antenatal and perinatal intervention and newborn survival. Niger J. Med., 15(2): 108-14.*
5. Lindsey,D; Benjamin,A; Jones J et al.(2013): *Maternal immunization as a strategy to decrease susceptibility to infection in newborn infant. Cur. Opin. Inf. Dis., 26(3): 248 – 253.*
6. Jpolak,I. &Verndell,M. (1984): *Immunolabelling for electron microscopy. J. Ultra structure Res., 37: 151 – 179.*

7. Malek,A.; Segar,R. and Schneider,H. (1994): *Maternal – fetal transport of immunoglobulin G and its sub-classes during 3rd trimester of human pregnancy. Am. J. Reprod. Immunology., 32(1): 8 – 14.*
8. Friden,B.; Makiya,R.;Nilsson,B. et al.(1994): *The human placental immunoglobulin G receptor and immunoglobulin G transport. Am. J. of Obst. &Gynec., 171: 258 – 263.*
9. Malek, A,; Segar,R.;Khun,P. et al. (1996): *Evolution of materno-fetal transport of immunoglobulin during human pregnancy. Am. J. Reprod. Immun., 36: 248 – 255.*
10. Stanley, A. (2005): *Maternal immunization to protect the mother and neonate, Expert Rev. Of Vaccine, 4 (6): 813 – 818.*
11. Riley,L. and Beigi,R. (2013): *Maternal pertusis vaccination; protecting neonates from infection. Clin. Infect. Dis., 56(4): 545 – 7.*
12. Pastrakuljic,A.; Schwartz,R.; Simon,C. et al. (1998): *Trans-placental transfer and bio-transformation studies of nicotine in the human placental cotyledon perfuse in vitro. Life Sci. , 63: 2333 – 2342.*
13. Ruckebusch,Y.; Phaneuf,P. &Dunlop,R. (1991): *In: Physiology of Small and large animals. Pp. 595. Year Book, Philadelphia, BC Decker St. Louis.*
14. Laliberte,F.; Mucchielli,A, &Laliberte,M. (1984): *Dynamics of antibody transfer from mother to fetus through the yolk-sac cells in the rat. Bio. Cell, 50: 255 – 261.*

15. Zhang,X.; Takashime,I. and Hashimoto, N.(1988): Role of maternal antibody in protection from hemorrhagic fever with renal syndrome virus infection in rats. *Arch. Virol.*, 103 : 253 – 265.
16. Simister,N. and Story,C. (1997): Human Placental Fc receptor and the transmission of antibodies from mother to fetus. *J. Reprod. Immunology.* , 37: 1 – 23.
17. Israel,E.; Simister,N.; Frieberg,F. et al. (1993): Immunoglobulin G binding sites on the human fetal intestine: a possible mechanism for the passive transfer of immunity from mother to infant. *Immunology.*, 79(1): 77 – 81.
18. Jones,E. and Woldman T. (1972): The mechanism of intestinal uptake and trans-cellular transport of Ig G in the neonatal rat. *J. Clin. Invest.*, 51: 16 – 27.
19. Roopenian D. and Akilesh,S. (2007): Fc Rn: the neonatal Fc receptor . *Nat. rev. Imm.*, 7: 715 – 725.
20. Montoyo,H.; Vaccarv,C.;Hafiener,M. et al. (2009): conditional deletion of MHC class I-related receptor Fc Rn reveals the sites of Ig G homeostasis in mice. *Proc. Nat. Acad. Sci.*, 106: 2788 – 2893.
21. Rachman, A.; Bernard,O. and Mandon,p. (1984): Immunoglobulins in mouse uterus and embryo during post-implantation period. *J. Reprod. Immun.*, 16: 39 – 47.
22. Parr,E. and Parr,M. (1986): Secretory immunoglobulin binding to bacteria in the mouse uterus after mating. *J. Reprod. Immunology.*, 18: 172 – 180.

23. Neil, A. (2003): protection of newborns through maternal immunization. *Vaccine*, 21: 3365 – 3396.
24. Kenney,R. and Khaleel, S. (1975): Activity of immunoglobulin of the mare uterus. *J. Reprod. Fert.*, 157: 157 – 159.
25. Wira,C; Sullivan,D. &Sandoe,C. (1983): accumulation of Ig A in the rat uterus in response to oestradiol-stimulation. *J. Steroid Biochem.*, 27: 159 – 167.
26. Hussein, A.; Newby,T. and Beurne,F. (1983): Immunohistochemical studies of the local immune system in the uterus of the sow *J. Reprod. Immunology.* 15: 151 – 179.
27. Symons,D. and Herbert, J. (1971): distribution of Ig G in the tissues of the genital tract of female rabbit. *J. Reprod. Fert.*, 28: 31 – 39.
28. Pippard, D. (1987): fate of stromal cells in the uterus of the rat during pregnancy. *J. Reprod. Fert.*, 48: 149 – 157.
29. Israel, E.; Patel, V.; Taylor,S et al. (1995): Requirement for a beta 2-microglobulin-associated Fc receptor for acquisition of maternal Ig G by fetal and neonatal mice. *J. of Imm.*, 154(12): 6246 – 6251.
30. Ben Hur,H.; Polnsky,E.; Berman,V. et al. (1999): trans-placental effects of Ig G generated against soluble protein on the splenic lymph system of rat progeny exposed to carcinogen. *Eur. J. Gynco. Oncl.*, 20(4): 306 – 10.
31. Keyler, D. ; Roiko, S. ; Benthahib, M. et al., (2005): Monoclonal nicotine – specific antibodies reduce nicotine distribution to brain in rats. *Drug Metab. & Dip.* , 33(7): 1056 – 1061.

32. Cervenek, J. ; Bender B.; Schneider, Z. et al., (2013): Neonatal Fc over-expression Boosts humoral immune response in transgenic mice. *J. of Immunology*, 186(2): 959 – 968.
33. Timo, R. ; Timothy, T. ; Kristi, B. et al., (2013): Immunologic functions of the neonatal Fc receptor for Ig G. *J. of Clin. Immunology*, 33(1): 9 – 17.
34. Keyler, D. ; Sherman, D. ; Lesage, M. et al., (2003): maternal vaccination against nicotine reduce nicotine distribution to fetal brain in rats. *J. of Pharmacology.*, 305(2): 578 – 592.
35. Palmara, P. ; Quinelle, G. ; Silvara, A. et al., (2012): Ig G placental transfer in healthy and pathological pregnancies. *Clin. And develop. Immunology*, 2012: 13 pages.
36. Stanely, A. (2005): Maternal immunization to protect the mother and neonate. *Expert Rev. Of Vaccines*, 4(6): 813 – 818.
37. Solder, E. and Rohr, I. (2009): Imaging of placental transport mechanism. *Eur. J. Obst. Gyn. Rep. Bio.*, 144(1): 114 – 120.
38. Healy, C. ; Marry, A. & Carel, J. (1006): prospects for prevention of childhood infection by maternal immunization. *Curr. Opin. In Infect. Dis.* , 19(3): 271 – 176.
39. Lindsey, B. ; Jone, C. & Kampamann, B. (2012): Bridging the gap: Maternal immunization is a mean to reduce neonatal deaths from infectious diseases. *Pathogens & Global Health*, 106(3): 137 – 138.

40. Malak A. (2013): *Role of Ig G antibodies in association with placental function and immunologic diseases in human pregnancy. Exp. Rev. Clin. Imm., 9(3): 235 – 249.*
41. Ekaterina, M. ; Susan, M. ; Olga, G. et al, (2006): *Maternal antibodies enhance or prevent cytomegalovirus infection in the placenta by neonatal Fc receptor-mediated transcytosis, Am. J. of Path., 168: 1210 – 1228.*
42. Healy, C. ; Rench, M. & Baker, C. (2013): *Importance of timing of maternal combined tetanus, diphtheria and cellular pertussis immunization and protection of young infants. Clin. Infect. Dis. , 56(4): 539 – 44.*
43. Frere, J. ; De Wals, P. ; Ovetckine, P. et al., (2013): *Evaluation of several approaches to immunize parents of neonates against B. pertussis. Vaccine, 31(51): 6087 – 91.*